

# Case Study

## Resolution of Recurrent Pseudoseizures in a 14-Year-Old Female Using Torque Release Technique: A Case Study

Chris Brown, D.C., CCSP<sup>1</sup>  
Alexandra Swenson, D.C.<sup>2</sup>

1. *Private Practice of Chiropractic, Tazwell, VA*
2. *Private Practice of Chiropractic, Fairbanks, AK*

### Abstract

**Objective:** To report on a female patient who presented for chiropractic care with a two-month history of recurrent pseudoseizures.

**Clinical Features:** A 14 year-old female presented for chiropractic care with a history of 30-40 pseudoseizure events per month.

**Intervention and Outcome:** Over a period of five months, a specific, conservative chiropractic adjustment regimen for the correction of vertebral subluxation was administered to the patient. The care plan was modified in accordance with outcome assessment measures, and during this time period the patient experienced a dramatic decrease in symptoms and frequency of seizures. Static electromyography (EMG) and thermal scanning were performed using the Chiropractic Leadership Alliance (CLA) Insight™ surface EMG and thermal scanning technology. Improvements were noted on the static and thermal surface EMG's over the course of the patient's care. The patient remains under chiropractic care at the time of this report, and has been seizure free for seven months.

**Conclusion:** While under chiropractic care, the patient experienced a resolution of all seizure activity. This case indicates the potential for chiropractic care to provide a non-invasive, non-drug based management of children with epilepsy and seizure disorders. However, further studies and research need to be done in order to explain how chiropractic can positively benefit those suffering from seizure disorders.

**Keywords:** *Chiropractic, subluxation, seizures, pseudoseizures, epilepsy, pediatrics, Torque Release Technique (TRT), surface electromyography, thermography*

### Introduction

Epilepsy, a term referring to chronic, recurrent seizures, is a neurological condition effecting 2.3 million people in the United States, with the highest rates of incidence reported in children under five years of age and in the elderly.<sup>1</sup> According to data gathered between 1986 and 1990, the prevalence of this condition in children under the age of 15 is estimated to be 4.0 per 1000.<sup>2</sup> The term epilepsy is used to describe any recurrent seizure pattern. A seizure is characterized by an abnormal discharge of nerve cells in the brain that can cause altered awareness or abnormal sensations, involuntary movements or convulsion.<sup>3,4</sup>

Pseudoseizures are thought to be psychogenic but their genesis remains unknown. They are identical in their presentation and symptomatology to grand mal seizures, but lack the presence of neurological activity visualized on an EEG. For this reason

they are believed to be related to a somatization disorder, personality disorder, or in some cases no psychopathology at all. They predominately effect females and have been found to have a higher association with a traumatic event.<sup>5</sup> There are multiple types of seizures and 30% of people with epilepsy can have two or more types.

Approximately 90% of those suffering from epilepsy have what is now termed tonic-clonic (formerly *grand mal*) seizures. The signs and symptoms of these seizures are identical to pseudoseizures and are characterized by an outcry, a loss of consciousness and falling, followed by tonic, then clonic contractions of muscles in the extremities, trunk and head. Urinary and fecal incontinence can also occur and the seizures typically last one to two minutes. Absence seizures, which were previously known as *petite mal* seizures, last approximately 10-30 seconds and are characterized by eyelid fluttering, loss of consciousness, but no fall or convulsion.<sup>3,4</sup>

Researching the chiropractic management of epilepsy is an area of research that could benefit from being expanded and developed. A recent report on the use of complementary and alternative medicine by patients with epilepsy in the midwestern United States reported that out of a sample of 228 patients, 24% of those patients sought chiropractic care.<sup>5</sup> While this percentage was less than those who reported engaging in spiritual direction for healing and prayer, chiropractic is beginning to be documented as a non-invasive beneficial option for management of adult and child patients with epilepsy.

The following case report details chiropractic care and management of a 14-year-old girl suffering from pseudoseizures that mimicked an identical presentation to both tonic-clonic and absence seizures. Her seizures were idiopathic in origin, meaning that no psychogenic or other cause, such as trauma, was found to contribute to the onset of the seizures. *Idiopathic epilepsy* occurs in approximately 75% of young adults with epilepsy and typically begins between the ages of 2 and 14 years.<sup>4</sup>

## Case Report

### History

A 14-year-old girl was brought in for chiropractic care by her mother who stated she had been suffering from 30-40 seizures per month for the previous three months. Her seizures often occurred in multiples on one day with one to two minutes of quiet in between two to three seizures at a time. The frequency and duration of the seizures had continued to worsen since they began and were always accompanied by a prodromal period where the patient would become quiet, her eyes would begin to twitch and she would begin to shake. The seizure would then ensue.

There were days when the patient would not have a seizure and then days when multiple seizures would occur. The patient reported feeling a sensation of anxiety and stress prior to the onset of a seizure, as well as severe fatigue to the point where she could not even muster the strength to talk. She had been home schooled since they began due to the nature and frequency of her seizures.

The patient was previously examined by her primary care doctor, an allergist, a neurologist, a psychiatrist and a psychologist. Previous testing included multiple MRI's, EEG's, CT's and blood work. No definitive pathology could be identified on any of the tests, and the patient's condition was diagnosed by multiple specialists as being caused by either an emotional or a physical problem. The patient's medical diagnosis was termed "pseudoseizures", due to the lack of brain activity on the EEG during a seizure episode.

Prior to presenting for chiropractic care the patient was taken multiple times to the emergency room where seizure episodes were controlled with Valium. During one of these emergency room visits the patient's father reported that the patient had endured trauma to the right temporal lobe during a fall during football season two years prior to the onset of her seizures but that no injuries were found during examination. Given the time period between the fall and onset of the seizures, it is

unlikely that trauma was the cause of the seizures.

In addition to the history of seizures the patient presented with allergies to grass, trees, dust mites, corn, milk, poultry, codfish and eggs. She also had a history of asthma, and the only medication reported that she was taking at the time of examination was Advair and Singular for asthma.

### Chiropractic Analysis

The patient was analyzed for vertebral subluxation using Torque Release Technique (TRT) protocol. TRT, as originally developed by Jay Holder, DC, is a tonal chiropractic technique that looks to release tension patterns in the spine.<sup>7</sup> The technique uses thirteen indicators for locating vertebral subluxations and a non-linear system for prioritizing the order of subluxations to be adjusted.<sup>8</sup> The adjusting protocol uses the Integrator, a handheld adjusting instrument with a pressure sensitive tip, an automatic release mechanism and a torque and recoil component.<sup>8,9</sup> TRT protocol performed on the patient's first visit revealed subluxations at C1, coccyx/sphenoid and sacrum.

These subluxations were determined by the presence of the following indicators:

1. Observation
  - a. Postural Faults
  - b. Abnormal breathing patterns
  - c. Congestive tissue tone
  - d. Inappropriate sustained patterns of muscle contraction
  - e. Functional leg length inequality
  - f. Abduction tendency/adduction resistance indicating C2 subluxation
  - g. Foot flare, indicating anterior rotation of spinal segments with Dural attachment.
  - h. Foot pronation/supination
2. Palpation
  - a. Abnormal heat, cold or energy imbalance
  - b. Tissue tone
  - c. Static and motion palpation
  - d. Heel tension, indicating C2, C5, sacrum or coccyx
3. Cervical Syndrome Test: indicates C1 or C5 posterior rotation with or without laterality.
4. Bilateral Cervical Syndrome Test (not Thompson's test): indicates coccyx, occiput, C5, C1 or T6—tested in that order.
5. Derifield Test: A positive Derifield indicates pelvic subluxation.<sup>7</sup>

The indicators listed above were developed based on the tonal model of subluxation which was first introduced by DD Palmer who wrote: "Life is an expression of tone....the cause of disease is any variation in tone."<sup>9</sup> This model of subluxation views the central nervous system as a whole, integrated and functional unit, which Holder refers to as the Crania-Spinal Meningeal Functional Unit (CSMFU).

The dura mater, the membrane that envelops the brain and spinal cord, anchors to the foramen magnum and coccyx, as well as to the spinal segments C2, C3, C5, sacrum and coccyx.<sup>10, 11</sup> Vertebral subluxations at the aforementioned levels have

been suggested to have a great effect on neural tension, and thereby on the overall wellness of the individual.<sup>8</sup> The effect of a disruption in the tension of the spinal cord is still hypothetical, however recent research on tethered cord syndrome, in which the spinal cord is stretched due to the inelastic dural attachment at the caudal end of the spine, has been suggestive of clinical dysfunction being caused by a change in spinal cord tension.<sup>11</sup>

A large amount of information and data gathered in objective analysis of the patient using TRT is obtained through leg checks. One aspect of the TRT leg check analysis, which sets it apart from other techniques, is that it is not acceptable for the leg length to simply improve. Only complete balancing of the leg length is acceptable or an indication that there is a subluxation that needs to be adjusted.<sup>8</sup> The leg checks are performed with the patient in the prone position and the legs extended.

A quick flexion/extension of the leg is performed to “trick” the body into thinking it’s weight bearing and thereby gain an accurate leg length analysis. The leg check is done by a forced dorsiflexion using the web of the hand across the plantar surface of the feet. A study performed at New Zealand Chiropractic College examined the inter-examiner reliability of leg length analysis between an experienced practitioner and a novice. This study found 72% reliability between the experienced doctor and new doctor in the combined straight leg and flexed knee positions, with an 87% reliability in the extended leg position alone.<sup>12</sup>

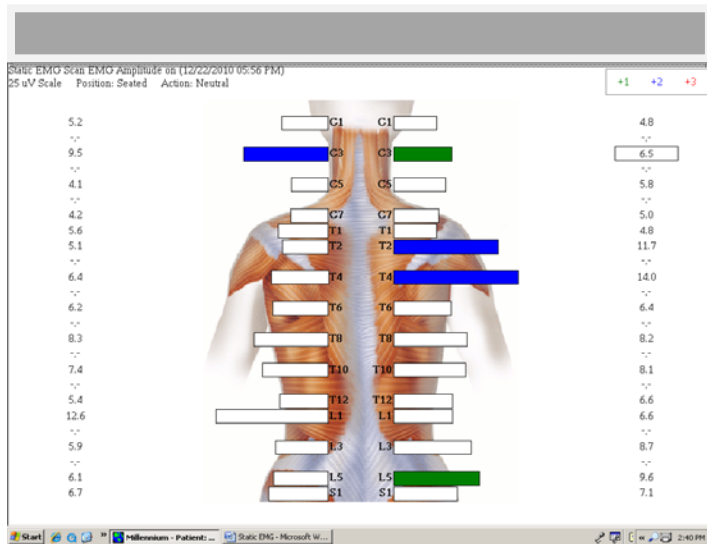
In addition to the leg checks and other TRT indicators which led to the determination of this patient’s vertebral subluxations, a surface EMG (SEMG) examination and thermal examination were performed. The SEMG showed abnormally high readings at the following areas: right C3, left C3, right T2, right T4, and right L5. The SEMG scan is useful in determining asymmetrical muscle contraction, areas of muscle splinting, severity of the condition, aberrant recruitment patterns, dysponesis, responses to dysafferentation, and responses to a chiropractic adjustment.<sup>13,14</sup>

Many studies have been conducted throughout the years to examine the reliability and validity of SEMG technology as a tool for assessing biomechanical activity of muscles throughout the body. The design of these studies, varying from untrained and trained subjects, and testing both intra and inter examiner reliability, have consistently demonstrated a very good test-retest reliability.<sup>14, 15</sup>

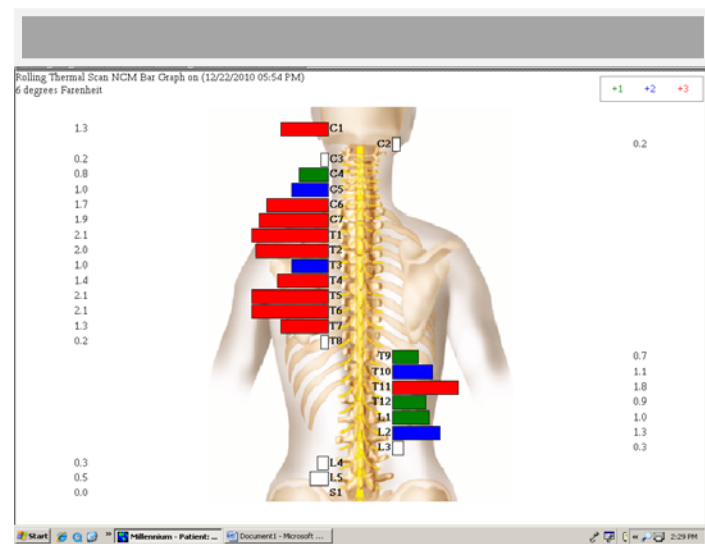
SEMG is also a valuable tool because a normative database has been developed through years of research. The scan provides signals measured in microvolts at 15 paired sites and compares them to a normative database. Three factors are considered in interpreting the scans: amplitude of the signal in microvolts, symmetry of the scan from left to right, and frequency of shift—which is shown by a fatigued muscle exhibiting a lower frequency than a non-fatigued muscle.<sup>14</sup>

This enables chiropractors utilizing this technology to know when improvements have been made in balancing the muscle tone and tension on either side of the spinal column, as well as providing a valuable tool for objectively gauging a patient’s physiological response to chiropractic care. A study examining the effects of spinal adjustments on areas of localized tight muscles demonstrated that the adjustment actually reduced the SEMG activity by 25% in areas that had been asymmetrical and high.<sup>15</sup>

The thermal scan was also performed to detect and measure heat differences in the tissues along the spine due to increased blood flow on one side of the spine versus the other as a result of dysautonomia. The thermography technology utilizes infrared heat to measure temperature differences along the back. This tool is used to gain a direct reading and understanding of how the autonomic nervous system (ANS) is functioning due to the role the ANS plays in vasoconstriction of the capillary beds underlying the skin of the paraspinal muscles. As vertebral subluxation is corrected in a patient this scan is expected to become symmetrical.<sup>16</sup> On the patient’s initial assessment temperature imbalances were found at C1, and C4 through L2.



Initial Surface EMG scan



Initial Rolling Thermal Scan

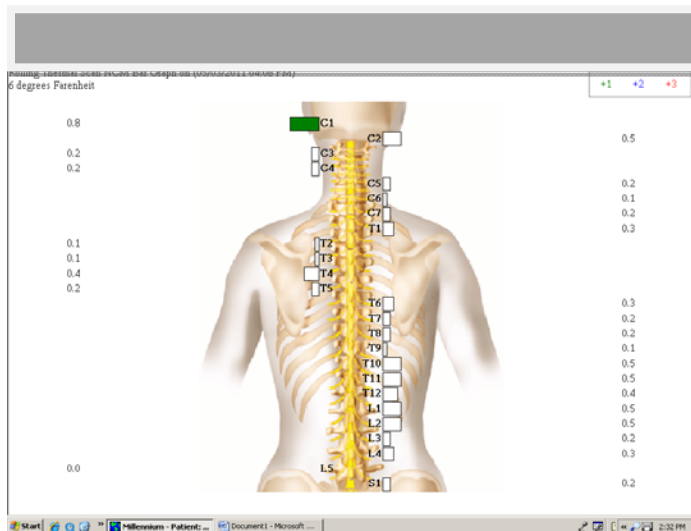
Prior to beginning care nutrition was also discussed with the patient and her mother; however the mother declined implementing nutritional changes as part of her daughter's care. During the course of the patient's care the only lifestyle change implemented was chiropractic care.

### *Chiropractic Care*

The patient began care and was analyzed and adjusted as indicated by TRT analysis two to three times per week. Subluxations found by TRT analysis indicated subluxations of C1, C2, C5, sphenoid, occiput and coccyx most often. By her sixth visit, the patient had gone without a seizure for eight days - the longest time period since her seizures began three months prior.

On her eighth visit the patient experienced a tonic-clonic (*grand mal*) like seizure (pseudoseizure) while in the office. It was noted that any time the patient experienced a seizure her left leg would be short. When no seizure activity had recently occurred her right leg would be short. During the course of her care her seizures became less and less frequent. Following the *grand mal* event in the office and the subsequent adjustment the patient again had an eight day seizure free period. Her next seizure free period was 23 days and on her 18<sup>th</sup> visit she presented without indicators for an adjustment.

Approximately 5 months after initiating care the thermal scan was updated and while preparation was being performed with an alcohol swab to clean the skin the patient began to shake and became slow to respond. A seizure did not ensue. Three weeks later the patient had a similar reaction as she did to the alcohol after spraying perfume on her arm but again no seizure ensued.



Rolling Thermal Scan After 5 Months

Metal toxicity was suspected as a possible cause for the seizures and a hair sample was taken with the results being negative.

### *Outcomes*

Following the two episodes where the patient displayed signs associated with the prodromal phase of a seizure no other

signs and symptoms have since presented. The patient has remained seizure free, returned to school 8 months following the initiation of care and was even participating in physical education class. The patient remains under chiropractic care as of this writing being analyzed for subluxation one time per week.

In addition to the resolution of her symptoms significant changes were shown on the static thermal scans during the course of her care. This data indicates that normal function had returned to her autonomic nervous system after five months of care.

## **Discussion**

### *Chiropractic Literature*

The chiropractic literature available on children with epilepsy is sparse. Research published on the reduction and resolution of signs and symptoms associated with epilepsy is predominantly case studies. Pistolese conducted a review of the literature in 2001 to find the currently available literature regarding chiropractic care and epilepsy.<sup>4</sup>

The review uncovered 17 published case studies using the *Index to Chiropractic Literature*, MANTIS and MEDLINE. 14 of these patients were receiving anticonvulsant medication and all had experienced no improvement with the medication. 15 of the 17 cases received upper cervical adjustments (C0, C1, and C2) using a variety of techniques. All of the cases reported positive outcomes in frequency, duration and severity of seizures.<sup>4</sup>

Two additional case reports have been published more recently. Hubbard details the care of a 25 year-old patient with juvenile myoclonic epilepsy that began when she was 14 years old with the onset of menses. This patient received upper cervical specific care through Blair technique over a period of 12 weeks. She was adjusted three times during that time period and after the first adjustment had a seizure. Following that seizure the patient reported no other seizure episodes.<sup>17</sup>

Another study by Hooper and Manis describes the case of a nine-year-old girl with occipital lobe epilepsy and associated abnormal left eye movement who also received upper cervical care through Blair technique. Similar to the previously mentioned case, this patient also received three upper cervical Blair adjustments over a five-month time period. After her third adjustment her signs and symptoms had decreased significantly and care was discontinued due to the mother's expectations being met. Communication was kept open between the doctor and the family and no incident of the patient's eye blinking or other signs of seizure returned.<sup>18</sup>

### *Proposed Mechanisms*

Currently there is no definitive mechanism to explain the effect chiropractic care can have on individuals with seizure conditions. There are currently six proposed theories, as outlined in the review of the literature by Pistolese. All of them suggest that the primary mechanism for reducing seizure activity from a chiropractic perspective involves the upper cervical spine.

The first, by Hyman<sup>4,19</sup> suggests that the cause of seizure reduction from chiropractic adjustments correlates with the structures of the upper cervical spine and their relationship to the central nervous system. The theory suggests that the chiropractic adjustment to that area reduces aberrant nerve impulses to the brain, leading to a decrease in seizure activity.

Alcantara et al,<sup>4,20</sup> have proposed a model in which activation of receptors in the spine cause afferent nerve impulses to the brain. It is suggested that during an adjustment these receptors send impulses to the appropriate pathways in the brain resulting in the decrease or cessation of seizure activity.

Amalu<sup>4,21</sup> has proposed two theories for the possible effect chiropractic can have on seizure conditions. The first is that of central nervous system facilitation due to hyperexcitation of periarticular mechanoreceptors and nociceptors. The cervical spine is particularly subject to this condition due to its biomechanical stability and high concentration of mechanoreceptors.

His second proposed theory suggests a neuronal hibernation during which a threshold of ischemia develops resulting in living cells that cease to function. The ischemia is proposed to be caused by hyperafferentation of the sympathetic nervous system regulating center. Both of these theories are largely untested, and their plausibility therefore unknown.

The dentate ligament-cord distortion hypothesis also applies to this case. As discussed earlier in the description of TRT as a tonal technique, the mechanism of dural sleeve adhesion to areas of the spine and specifically the attachment to the vertebrae via the dentate ligament can function as a model to explain how chiropractic positively effects patients with seizures. By this model, subluxation of one of the vertebrae with dural attachments can cause adverse mechanical cord tension and thereby create pathophysiology.

The pathophysiology will present in three parts, as vascular hypoxia, overstretching of the nerve fibers, and an abnormal flow of neurotransmitters of the Brain Reward Cascade. The Brain Reward Cascade is associated with well-being and disruption of this cascade can result in feelings of anxiety, anger, or negative emotions.<sup>9</sup> This in turn can lead to dysfunction and disease in the brain and central nervous system which could present as a seizure condition. The multifactorial influence of vertebral subluxation under this model combines many of the aforementioned theories under one heading, however more research is needed to definitively explore all of these theories.

While the exact mechanism is yet to be understood, what this case, and those reviewed during this discussion demonstrate, is the positive effect chiropractic care has on seizure disorders in children. Given some of the unknowns in this patient's case, such as the question as to the exact nature of her seizures, or "pseudoseizures" as they were termed by the medical community, further investigation into the patient's condition, as well as further development of a theory behind how chiropractic can positively impact seizure disorders, could make for a stronger case for the use of chiropractic care in children with epilepsy.

## Conclusion

It is postulated that a relationship between subluxation, specifically upper cervical subluxation, and childhood seizure disorders exists, but it remains largely undocumented and not well understood. Evidence from this case supports the elimination of vertebral subluxations as an effective management approach in the care of children with seizures. This is a neurological condition and it is suggested more research be done in the chiropractic profession to develop a non-invasive, conservative care option for epilepsy and seizures before more invasive procedures such as dependency on drugs and surgery are considered in children with seizures and/or pseudoseizures.

## References

1. Epilepsy Foundation. Living Well With Epilepsy II Conference Report of the 2003 National Conference on Public Health and Epilepsy. Accessed Nov 2011 [www.cdc.gov/epilepsy/pdfs/living\_well\_2003.pdf]; Pg 6.
2. Centers for Disease Control and Prevention. Current Trends Prevalence of Self Reported Epilepsy—United States, 1986-1990. MMWR Morb and Mortal Wkly Rep 1994;43(44):810-811.
3. Neurological Disorders: seizure disorders (epilepsy); signs and symptoms. The Merck Manual of diagnosis and therapy, professional edition. Whitehouse Station (NJ). 2008. For Mobile and Web.
4. Pistolesse, R. A. Epilepsy and Seizure Disorders: A Review of the Literature Relative to Chiropractic Care of Children. J. of Manipulative and Physiol Ther. 24(3):March/April, 2001.
5. Harden, C. Contribution of Current and Pst Traumatic Events to Pseudoseizures and Epilepsy. Epilepsy Curr. 2003 March; 3(2): 50.
6. Liow, K, et al. Pattern and frequency of use of complementary and alternative medicine among patients with epilepsy in the midwestern United States. Epilepsy and Behavior 10 (2007) 576-582.
7. Fletcher, D. A Tonal Solution for Subluxation Patterns: Torque Release Technique analyzes Cranial-Spinal Meningeal Functional Unit. Canadian Chiropractor. Accessed Nov 2011 [www.canadianchiropractic.com]. 20-23.
8. Holder, JM, Nadler, A, Talsky, M. Torque Release Technique: A Technique Model for Chiropractic's Second Century. Canadian Chiropractor. February 1998;3(1).
9. Palmer DD. Textbook of the Art, Science, and Philosophy of Chiropractic. The Chiropractor's Adjuster. Portland,OR: Portland Publishing House, 1910
10. Gray, H. Anatomy of the human body. J.W. Edwards Inc. Michigan. 2003;639-643, 707-719.
11. Hodgson, N. The Role of the Spinal Dura Mater in Spinal Subluxation. Accessed Nov 2011 [www.torque-release.com.au]. 2007.
12. Holt, KR et al. Interexaminer Reliability of a Leg Length Analysis Procedure Among Novice and Experienced Practitioners. J. of Manipulative Physiol Ther. 2009 Mar; 32(3):216-222.

13. DeVocht JW, Pickar JG, Wilder DG. Spinal manipulation alters electromyographic activity of paraspinal muscles: a descriptive study. *J Manipulative Physiol Ther.* 2005 Sep; 28(7):465-71.
14. Kent, C. Surface Electromyography in the Assessment of Changes in Paraspinal Muscle Activity Associated with Vertebral Subluxation: A Review. *J Vert Sublux Res* 1997; 1(3):1-8.
15. Meeker WC, Gahlinger PM. Neuromusculoskeletal Thermography: A Valuable Diagnostic Tool? *J. Manipulative Physiol Ther.* 1986; 9:4 257-266.
16. McCoy, M. Paraspinal Thermography in the Analysis and Management of Vertebral Subluxation: A Review of the Literature. *A. Vertebral Subluxation Res.* Jul 2011: 57-66
17. Hubbard, A, Crisp A, Vowels, A. Upper cervical chiropractic care for a 25-year-old woman with myoclonic seizures. *Journal of Chiropractic Medicine.* 2010;9:90-94.
18. Hooper, S, Manis, A. Upper Cervical Care in a Nine-Year-Old Female Patient with Occipital Lobe Epilepsy: A Case Study. *J Upper Cervical Chiropractic Research.* Feb, 3, 2011. 10-17.
19. Hyman, C. Chiropractic Adjustments and the reduction of Petit Mal Seizures in a Five Year Old Male: A Case Study. *J Clin Chiropr Pediatr.* 1996;1(1):28-32.
20. Alcantara J, Heschong R, Plaughner G, Alcanatara J. Chiropractic Management of a Patient with subluxation, low back pain, and epileptic seizures. *J Manipulative Physiol Ther* 1998;21:410-8.
21. Amalu, W. Cortical Blindness, Cerebral Palsy, Epilepsy, and Recurring Otitis Media: A Case Study in Chiropractic Management. *Today's Chiropr.* 1998;27(3):16-25.